

# Potent anti-inflammatory effects of systemically administered curcumin modulate periodontal disease *in vivo*

M. R. Guimarães<sup>1</sup>, L. S. Coimbra<sup>1</sup>,  
S. G. de Aquino<sup>1</sup>, L. C. Spolidorio<sup>2</sup>,  
K. L. Kirkwood<sup>3</sup>, C. Rossa Jr<sup>1</sup>

<sup>1</sup>Departments of Diagnosis and Surgery, Faculdade de Odontologia de Araraquara-Univ Estadual Paulista (UNESP), Araraquara, SP, Brazil<sup>2</sup>Departments of Physiology and Pathology, Faculdade de Odontologia de Araraquara-Univ Estadual Paulista (UNESP), Araraquara, SP, Brazil and <sup>3</sup>Department of Craniofacial Biology and Center for Oral Health Research, College of Dental Medicine – Medical University of South Carolina (MUSC), Charleston, SC, USA

Guimarães MR, Coimbra LS, de Aquino SG, Spolidorio LC, Kirkwood KL, Rossa C Jr. Potent anti-inflammatory effects of systemically administered curcumin modulate periodontal disease *in vivo*. *J Periodont Res* 2011; 46: 269–279. © 2011 John Wiley & Sons A/S

**Background and Objective:** Curcumin is a plant-derived dietary spice with various biological activities, including anticarcinogenic and anti-inflammatory effects. Its therapeutic applications have been studied in a variety of conditions, including rheumatoid arthritis, colon cancer and depression, but no studies have evaluated the effects of curcumin on periodontal disease *in vivo*.

**Material and Methods:** Experimental periodontal disease was induced in rats by placing cotton ligatures around both lower first molars. Curcumin was given to the rats by the intragastric route daily at two dosages (30 and 100 mg/kg) for 15 d. Control animals received ligatures but only the corn oil vehicle by gavage, and no treatment-negative control animals were included. Bone resorption was assessed by micro-computed tomography, and the inflammatory status was evaluated by stereometric analysis. Both RT-qPCR and ELISA were used to determine the expression of interleukin-6, tumor necrosis factor- $\alpha$  and prostaglandin E<sub>2</sub> synthase in the gingival tissues. Modulation of p38 MAPK and nuclear factor- $\kappa$ B activation were assessed by western blotting.

**Results:** Bone resorption was effectively induced in the experimental period, but it was not affected by either dose of curcumin. Curcumin effectively inhibited cytokine gene expression at both the mRNA and the protein level and produced a dose-dependent inhibition of the activation of nuclear factor- $\kappa$ B in the gingival tissues. Activation of p38 MAPK was not inhibited by curcumin. Curcumin-treated animals also presented a marked reduction of the inflammatory cell infiltrate and increased collagen content and fibroblastic cell numbers.

**Conclusion:** Curcumin did not prevent alveolar bone resorption, but its potent anti-inflammatory effect suggests that it may have a therapeutic potential in periodontal diseases.

Carlos Rossa Jr, DDS, PhD, Department of Diagnosis and Surgery, Faculdade de Odontologia de Araraquara, Univ Estadual Paulista (UNESP), Rua Humaitá 1680, Centro 14801-903 Araraquara, Sao Paulo, Brazil  
Tel: +55 16 3301 6509  
Fax: +55 16 3301 6433  
e-mail: crossajr@foar.unesp.br

**Key words:** curcumin; inflammation; periodontal disease; nuclear factor- $\kappa$ B; p38 mitogen-activated protein kinase

Accepted for publication November 21, 2010

Phytochemicals are naturally occurring substances found in plants. There has been considerable public and scientific

interest in the use of phytochemicals derived from dietary components to combat human diseases, especially

the two major causes of death in the developed world, cardiovascular diseases and cancer (1). Curcumin

(diferuloylmethane) is one such phytochemical and is a major constituent of the yellow spice turmeric derived from the rhizomes of *Curcuma* spp. (2).

Curcumin has potent anti-inflammatory, anticarcinogenic and antioxidant activities, and a number of preclinical trials have been conducted to assess its therapeutic potential (3–5). Following oral administration, curcumin has been shown to prevent cancer in the colon, skin, stomach, liver, lung, duodenum, soft palate and breasts of rodents (6,7). In a rat model of acute ulcers, curcumin potently attenuated the ulcer activity by preventing glutathione depletion, lipid peroxidation and protein oxidation. Both oral and intraperitoneal administration of curcumin blocked gastric ulceration in a dose-dependent manner (8). In animal studies of arthritis, oral administration of curcumin decreased the levels of the inflammatory glycoprotein Gp A72, with a reduction in the inflammatory response in the paws (9).

The anti-inflammatory properties of curcumin seem to be mediated by modulation of the activity of signaling pathways and transcription factors, especially nuclear factor- $\kappa$ B (NF- $\kappa$ B), activating protein-1 (AP-1) and MAPKs (10). Downregulation of the activation of NF- $\kappa$ B and MAPKs by curcumin suppresses the expression of interleukin-6 (IL-6), interleukin-1 $\beta$  (IL-1 $\beta$ ), tumor necrosis factor- $\alpha$  (TNF- $\alpha$ ), MMP-2 and MMP-9 in the late phase of experimental acute pancreatitis (11), in the modulation of arthritis (12–15), in the prevention and healing of indomethacin-induced gastric ulcer (8) and in the treatment of inflammatory bowel disease and Crohn's disease (16–18).

Periodontal disease initiation and progression occur as a consequence of the host response to microorganisms of the dental biofilm. Besides their role as stimulants of the host response, periodontal pathogens release harmful byproducts and enzymes that break down extracellular matrix components, such as collagen, as well as host cell membranes. Once the host response is initiated, various inflammatory molecules, such as cytokines and prostaglandins, are released from leukocytes, fibroblasts or other host tissue-derived cells (19–21). Chronic periodontal

inflammation perpetuates and amplifies itself through numerous autocrine and paracrine regulatory loops of the inflammatory mediators, acting on cells within the periodontal microenvironment. An improper immune response leads to overproduction of inflammatory cytokines and consequently periodontal attachment loss and bone resorption. Host modulation therapeutic strategies aimed at inhibition of the progression of inflammatory bone loss associated with periodontitis include the blockage of inflammatory cytokines. Recently, the cell signaling pathways that regulate the expression of inflammatory mediators have become promising therapeutic targets (19).

Although a range of biological and pharmacological activities of curcumin have been reported, its therapeutic potential for destructive periodontal disease is poorly understood. To the best of our knowledge, this is the first study to evaluate the effect of curcumin on the modulation of periodontal disease *in vivo*.

Besides its anti-inflammatory properties, curcumin has also been shown to improve wound healing by increasing collagen deposition, angiogenesis and the density of fibroblasts, reducing the radiation-induced delay in wound repair (22). Interestingly, curcumin-treated wounds presented not only a greater number of fibroblasts but also more infiltrating macrophages and neutrophils compared with untreated wounds (23,24). These studies demonstrated that treatment with curcumin resulted in faster closure of wounds, better regulation of granulation tissue formation and induction of growth factors (24), all features that can be extremely useful in the setting of periodontal disease.

These findings prompted us to investigate the effect of systemically administered curcumin on the inflammatory response during the course of ligature-induced periodontal disease in rats. The present study was undertaken to determine whether curcumin could inhibit connective tissue breakdown in ligature-induced periodontitis in rats. To obtain greater insight into the anti-inflammatory effects of curcumin, we assessed the modulation of signaling

pathways (p38 MAPK and NF- $\kappa$ B) and the expression of IL-6, cyclooxygenase-2 and TNF- $\alpha$  in the periodontal tissues.

## Material and methods

### Experimental design

All the experimental protocols were approved by the Ethical Committee for Animal Experimentation (CEEA) of the School of Dentistry at Araraquara – UNESP and performed in accordance with the guidelines from the Brazilian College for Animal Experimentation (COBEA).

Sixty male Holtzman rats (*Rattus norvegicus albinus Holtzman*), weighing between 100 and 200 g, were randomly distributed into the following six experimental groups comprising 10 animals each: (i) vehicle control (no ligatures); (ii) vehicle periodontitis (with ligatures); (iii) curcumin 30 mg/kg control (no ligatures); (iv) curcumin 30 mg/kg periodontitis (with ligatures); (v) curcumin 100 mg/kg control (no ligatures); and (vi) curcumin 100 mg/kg periodontitis (with ligatures). The rats were kept in a room with controlled temperature ( $21 \pm 1^\circ\text{C}$ ) and humidity (65–70%) and a 12 h–12 h light–dark cycle. Animals were fed standard rat chow and water *ad libitum*. To induce periodontitis, three groups of rats were anesthetized by intramuscular administration of ketamine (80 mg/kg body weight; Francofar, Virbac of Brazil Ind. and Com. Ltd, São Paulo, Brazil) and xylazine (20 mg/kg body weight; Virbaxil, Virbac of Brazil Ind. and Com. Ltd), and cotton threads were tied around the first molars bilaterally.

Administration of curcumin started the day before the placement of ligatures for the induction of periodontal disease. Curcumin was administered by the intragastric route daily by gavage in two different dosages: one group received the lower dose of 30 mg/kg body weight, and the other group received 100 mg/kg body weight. Control animals were given the same volume of the corn oil vehicle. Fifteen days after the placement of ligatures, the animals were killed by an overdose of anesthetics and the mandibles

hemisected. This period was selected based on a previous publication (25) demonstrating that 15 d corresponds to the peak of inflammatory severity in this experimental model. Eight block sections including first and second molars with their surrounding tissues were submitted to routine histological processing for descriptive and stereometric evaluation, whereas in the remaining block sections the soft tissues surrounding the teeth and overlying the bone from other blocks were carefully dissected and used for the extraction of total RNA and protein.

These tissue blocks were immersed directly in 10% buffered formalin fixative solution for 48 h and decalcified in tetrasodium-EDTA aqueous solution (0.5 M, pH 7.4) for 2–3 mo, under agitation at room temperature. Each specimen consisted of a section containing the first and second molars and their surrounding alveolar process and was included in paraffin blocks. Serial 4  $\mu\text{m}$  sections were obtained in the bucco-lingual direction and stained with hematoxylin and eosin.

### Stereometry

The analysis was conducted by a single examiner, who was blinded to the experimental groups, using an optical microscope (Diastar; Cambridge Instruments, Buffalo, NY) set at  $\times 200$  magnification. Semi-serial sections of 4  $\mu\text{m}$  were obtained from the tissue blocks on a buccal–lingual orientation. A total of three sections, spaced 100  $\mu\text{m}$  from each other, were evaluated per tooth. A 50  $\mu\text{m} \times 50 \mu\text{m}$  grid was overlaid over the histological images, allowing the analysis of an ‘area of interest’ of 2500  $\mu\text{m}^2$ . Two grids composed of five-by-five 10  $\mu\text{m}$  squares were used in each histological image; one was positioned with its lower border 25  $\mu\text{m}$  below the top of the alveolar bone crest and perpendicular to the root surface, and the other was positioned with its upper border at the base of the junctional epithelium, representing the ‘bone crest’ and ‘submarginal’ areas, respectively. In both cases, the lateral border of the grids was always positioned over the most prominent part of the root surface in the area. Each one of

the 25 points of the grid projected on each section was counted, and the proportion of collagen, fibroblastic cells and inflammatory cells (distinguished by morphological characteristics) in the area of interest was determined as a percentage of the total points counted. A total of three images obtained from equally spaced slides (spanning 900  $\mu\text{m}$  of the buccal–lingual aspect of the molars) were evaluated from each animal. Slides from at least three animals in each experimental group were used.

### Micro-computed tomography and bone volume fraction analysis

After dissection of the soft tissues used for RT-qPCR and western blot experiments, the mandibles were tumbled in 10% formalin at 4°C overnight, transferred to a 70% ethanol solution and stored at 4°C. Specimens were scanned using micro-computed tomography with 18- $\mu\text{m}$ -thick sections at the Orthopaedic Research Laboratories of the University of Michigan (Ann Arbor, MI, USA). After three-dimensional reconstruction, the results were analysed using GE Microview software (GE Healthcare, Piscataway, NJ, USA) to quantify bone volume fraction. In each scan, a three-dimensional standardized region of interest was defined by the following landmarks: the apex of the distal root of the first molar (apical limit); the bottom of the furcation of the first molar (coronal limit); the most distal aspect of mesial root of the second molar (posterior limit); and the most mesial aspect of the mesial root of the first molar (anterior limit). The analysis of bone volume fraction (BVF) was calculated with a threshold of 1621 arbitrary units for the detection of mineralized tissue within the region of interest.

### Evaluation of cytokine gene expression at the mRNA level (RT-qPCR)

Total RNA was extracted from tissue samples using TRIzol<sup>®</sup> reagent (Invitrogen Corp., Carlsbad, CA, USA) according to the manufacturer’s instructions. The concentration of RNA was determined by spectropho-

tometry, and 700 ng of total RNA was reverse transcribed into cDNA using random hexamers as primers (High Capacity cDNA synthesis kit; Applied Biosystems, Carlsbad, CA, USA). The relative abundance of the transcripts of the candidate inflammatory genes were measured by real-time RT-PCR using Taqman chemistry and predesigned sets of primers and probes (TaqMan Gene Expression Assays; Applied Biosystems) on a StepOne Plus Real-Time PCR System (Applied Biosystems). The reactions were carried out in a 96-well plate in a final reaction volume of 30  $\mu\text{L}$  that included Taqman Universal PCR Master Mix (Applied Biosystems), cDNA template (corresponding to 30 ng of cDNA and Taqman Gene Expression Assays (Applied Biosystems) for each target gene: *TNF- $\alpha$* , NM\_013693; *IL-6* (interleukin 6), NM031168; *Ptgs-2* (prostaglandin-endoperoxide synthase-2), NM\_011198; and *Gapdh* (glyceraldehyde-3-phosphate dehydrogenase), NM\_008084). Optimized thermal cycling conditions were as follows: 50°C for 2 min, 95°C for 10 min, followed by 40 cycles at 95°C for 15 s and 60°C for 1 min. For each sample, analyses of gene expression were performed in duplicate. The experiments were with samples isolated from at least three different animals in each experimental group. To normalize the amount of mRNA present in each reaction, the expression of *GAPDH*, which was not altered by the experimental conditions, was used as a housekeeping gene. To compare the expression levels among different samples, the relative expression level of the genes was calculated using the comparative  $\Delta C_t$  method using the StepOnePlus software, Applied Biosystems, Carlsbad, CA, USA.

### Activation of signaling pathways (western blot) and determination of cytokine gene expression at the protein level (ELISA)

Total proteins were extracted from gingival tissue samples using a detergent-based extraction buffer (Tissue Protein Extraction Reagent [T-PER]; Pierce Biotechnology; Thermo Fischer Scientific, Rockford, IL, USA) containing a

protease inhibitor cocktail (Protein Stabilizing Cocktail; Santa Cruz Biotechnology) (Santa Cruz, CA, USA) according to the manufacturer's instructions (Pierce Biotechnology). The tissue samples were macerated in the buffer (50  $\mu$ L/mg of tissue) and centrifuged for 5 min at 16,000 *g* at 4°C. The proteins were quantified using the Lowry method (DC assay; Bio-Rad Laboratories) (Hercules, CA, USA), and 40  $\mu$ g of total protein was added to an SDS sample buffer containing 2% SDS, dithiothreitol as a reducing agent, glycerol and bromophenol blue dye (Cell Signaling, Beverly, MA, USA), heat-denatured at 97°C for 5 min and chilled on ice for 5 min before loading on 10% SDS-polyacrylamide gels.

Electrophoresis on discontinuous acrylamide gels was carried out at 100 V for 90 min and subsequently electro-transferred to 0.2  $\mu$ M nitrocellulose membranes using 300 mA constant current for 1 h. The membranes were blocked for 1 h in Tris-buffered saline (TBS) containing 5% nonfat dry milk and 0.1% Tween-20 and subsequently washed for 5 min (three times) with TBS-0.1% Tween (TBS-T) at room temperature. The membranes were then incubated with primary antibodies overnight at 4°C (1:100 dilution in phosphate-buffered saline; phospho-p65 and phospho-p38; Cell Signaling). Membranes were washed in TBS-T buffer for 5 min (three times) and incubated with secondary antibodies conjugated to horseradish peroxidase (1:1000 dilution in the blocking buffer) for 1 h at room temperature, washed again with TBS-T buffer (5 min, three times). Detection of bands was carried out on radiographic film by using a chemiluminescence system (Lumi-Glo; Cell Signaling).

Proteins from these same samples were also used in the ELISAs to determine the concentration of prostaglandin E<sub>2</sub> (PGE<sub>2</sub>), IL-6 and TNF- $\alpha$ . These assays were performed according to the manufacturer's instructions (R&D Systems, Minneapolis, MN, USA), and the results were normalized to the total concentration of protein in the samples. Samples from at least three animals in each experimental group were used and assayed in duplicate.

### Data analysis

The purpose of data analysis was to compare the results from curcumin-treated animals with those of vehicle-treated control animals. Considering the two experimental groups treated with different doses of curcumin (30 and 100 mg/kg body weight) as independent variables, we used Student's unpaired *t*-tests for the comparisons between all the groups (control vs. 30 mg/kg of curcumin, control vs. 100 mg/kg of curcumin and 30 vs. 100 mg/kg of curcumin) with a significance level of 5%.

## Results

### Alveolar bone loss associated with ligature-induced periodontal disease is not prevented by administration of curcumin

In the three-dimensional reconstructions, the fraction of the region of interest that is occupied by bone tissue (BVF) was significantly reduced (> 50% reduction of BVF in comparison with control and vehicle-treated animals without the ligatures,  $p < 0.05$ ) in the vehicle-treated animals that received ligatures, indicating that the ligatures induced alveolar bone resorption in the 15 d experimental period. The administration of curcumin had no effect on the extent of alveolar bone resorption, since animals treated with both doses of curcumin still presented a significant decrease of BVF in comparison with control animals without ligatures, and no differences were detected in comparison with the BVF of vehicle-treated animals with ligatures (Fig. 1). Administration of curcumin or of the corn oil vehicle had no effect on alveolar bone in the absence of ligature-induced periodontal disease.

### Curcumin inhibits the ligature-induced inflammatory process and enhances the deposition of collagen

A stereometric analysis was performed to correlate the information on the effects of curcumin on the activation of signaling pathways and on the expression of proinflammatory cytokines

with the overall modulation of the inflammatory status in the periodontally diseased tissues. Ligature-induced periodontitis induced a clear and obvious inflammatory process, characterized by increased cell and vascular densities and reduced collagen content. Administration of curcumin had a suppressive effect on the inflammation, as evidenced by the absence of inflammatory cells in the submarginal and bone crest areas (Figs 2 and 3). Collagen content in the tissues was also increased in curcumin-treated animals, which may be due to the inhibition of inflammation and, consequently, of the associated collagen degradation (Figs 2 and 3). These results indicate a clear correlation between the histological inflammation status and the expression of proinflammatory mediators.

### Curcumin inhibits ligature-induced activation of NF- $\kappa$ B, but not of p38 MAPK

Since NF- $\kappa$ B is considered a prime target of curcumin and also based on the relevance of both NF- $\kappa$ B and MAPK signaling pathways for inflammatory cytokine expression, we next evaluated the modulation of these pathways by orally administered curcumin in periodontally diseased tissues.

The placement of a ligature elicited the inflammatory process and increased activation of NF- $\kappa$ B. Administration of curcumin produced a marked, dose-dependent inhibition of NF- $\kappa$ B activation in periodontally diseased tissues. Surprisingly, activation of p38 MAPK was reduced in periodontally diseased tissues. The lower dose of curcumin (30 mg/kg) did not change the reduced activation status of p38 MAPK associated with ligature-induced periodontal disease, whereas the higher dose (100 mg/kg) restored the activation status observed in healthy periodontal tissues (Fig. 4).

### Curcumin completely abrogates PGE<sub>2</sub> synthase (murine cyclooxygenase-2 analogue) mRNA expression in ligature-induced periodontal disease

To investigate the effect of curcumin on ligature-induced inflammatory gene

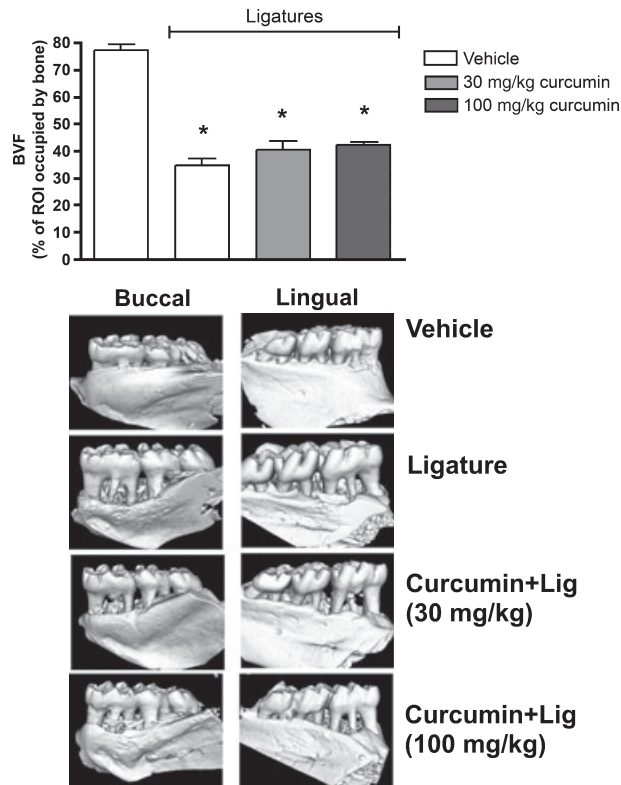


Fig. 1. Micro-computed tomography analysis of mandible specimens obtained from the experimental animals shows that neither dose of intragastrically administered curcumin prevented alveolar bone loss in the ligature model of periodontal disease. The three-dimensional images are representative of eight samples in each group (four animals per group) and depict the significant resorption of alveolar bone on both the buccal and the lingual aspects of the first molars. The bar graphs represent the quantification of the area occupied by bone tissue in a standardized region of interest (ROI) defined by anatomical landmarks including the first molar and the interproximal area between first and second molars. Bars represent means and vertical lines standard deviations of the percentage of the region of interest occupied by bone tissue. \*A significant ( $p < 0.05$ ) difference in comparison with negative control specimens from animals treated with vehicle and without ligatures.

expression, the total RNA and protein were extracted from gingival tissues surrounding the lower first molars of rats with or without ligature placement. RNA samples were used for RT-qPCR and protein samples for the ELISA experiments. Interestingly, animals treated with the higher dose of curcumin (100 mg/kg) presented a marked increase in PGE<sub>2</sub> synthase mRNA levels in comparison with control animals. Ligature placement increased PGE<sub>2</sub> synthase mRNA in the tissues, but treatment with curcumin completely inhibited this increase (Fig. 5). We could not detect PGE<sub>2</sub> expression at the protein level in our samples, probably due to the reduced level of expression.

#### Curcumin effectively inhibits *IL-6* and *TNF- $\alpha$* gene expression

At protein level, the treatment with 100 mg/kg of curcumin induced IL-6 protein expression in nondiseased periodontal tissues; however, there was a dose-independent and significant inhibition of IL-6 mRNA (Fig. 5) and protein expression (Fig. 6) in periodontally diseased tissues of animals treated with both doses of curcumin. Interestingly, greater inhibition of IL-6 was associated with the lower dose (30 mg/kg) of curcumin. The mRNA expression of TNF- $\alpha$  in ligature-induced periodontal disease was completely inhibited by curcumin (Fig. 5). Both doses of curcumin inhibited

TNF- $\alpha$  protein expression in periodontal tissues surrounding ligated teeth; however, like the regulation of IL-6, this inhibition reached statistical significance only for the 30 mg/kg dose (Fig. 6).

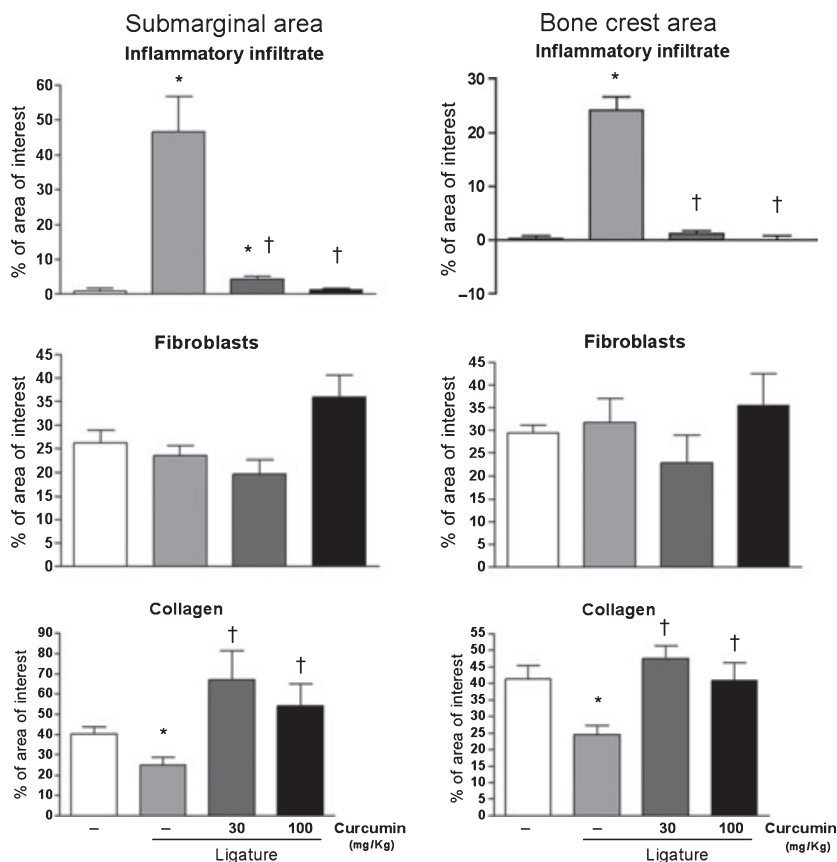
#### Discussion

In this study, we investigated the anti-inflammatory effect of curcumin in ligature-induced periodontitis in rats. Curcumin did not affect body weight or the behavior of the experimental animals in comparison with vehicle-treated rats. No animal died during the experimental period, suggesting a lack of severe adverse effects associated with curcumin administration, which is supported by studies using similar or higher doses of curcumin in other rat models, where no changes were observed in lymph nodes, pancreas, liver, kidneys or lungs (11,26).

The present study demonstrates, for the first time, that intragastrically administered curcumin effectively reduces inflammation and connective tissue breakdown in this experimental periodontitis model. Moreover, we provide evidence that this effect might be explained, at least in part, by the inhibition of IL-6, PGE<sub>2</sub> and TNF- $\alpha$  expression, as a result of the modulation of NF- $\kappa$ B activation. Surprisingly, however, we did not observe any effect of curcumin administration on alveolar bone resorption.

The relevance of these cytokines is supported by studies showing that they have all been found to be significantly elevated in diseased periodontal sites compared with healthy or inactive sites (27–33) and have been positively correlated with increased probing depth and attachment loss (19,30,32).

Recent studies have found that curcumin is able to suppress NF- $\kappa$ B (1,34–37) and MAPKs (1,34,37), thus reducing the production of inflammatory cytokines, such as IL-6 (11,26,34,36), TNF- $\alpha$  (11,26,34,38) and PGE<sub>2</sub> (37). Anti-inflammatory properties of curcumin protected the liver of rats against injury caused by carbon tetrachloride by dramatically suppressing serum levels of TNF- $\alpha$ , IL-6 and



**Fig. 2.** Stereometry analysis of the histological characteristics of gingival tissues subjected to ligature-induced periodontal disease according to the dose of curcumin (30 or 100 mg/kg) administered intragastrically for 15 d. Control animals received vehicle and negative control animals were also given vehicle but no ligature was placed around the first molars. Two  $50 \mu\text{m} \times 50 \mu\text{m}$  grids were overlaid on histological images captured from hematoxylin and eosin stained slides at  $\times 200$  magnification, allowing the analysis of two 'areas of interest' of  $2500 \mu\text{m}^2$  each; one was positioned  $25 \mu\text{m}$  below the top of the alveolar bone crest, and the other at the base of the junctional epithelium, representing the 'bone crest' and 'submarginal' areas, respectively. The proportion of collagen, fibroblastic cells and inflammatory cells (distinguished by the morphological characteristics) in the area of interest was determined. A total of three images obtained from equally spaced slides (spanning  $900 \mu\text{m}$  of the buccal-lingual aspect of the molars) were evaluated from each animal. Slides from at least three animals in each experimental group were used. Both doses of curcumin markedly reduced the inflammatory infiltrate in periodontally diseased tissues. The lower dose of curcumin (30 mg/kg) induced a greater increase in the collagen content, whereas the higher dose (100 mg/kg) was associated with increased proliferation of fibroblastic cells. Bars indicate means and vertical lines the standard deviations. Student's *t*-test was used for pairwise comparison, and showed a significant difference ( $*p < 0.05$ ) in comparison with healthy (no ligature) control sites, whereas there was a significant difference ( $\dagger p < 0.05$ ) between curcumin-treated and vehicle-treated groups at periodontal disease (ligature) sites.

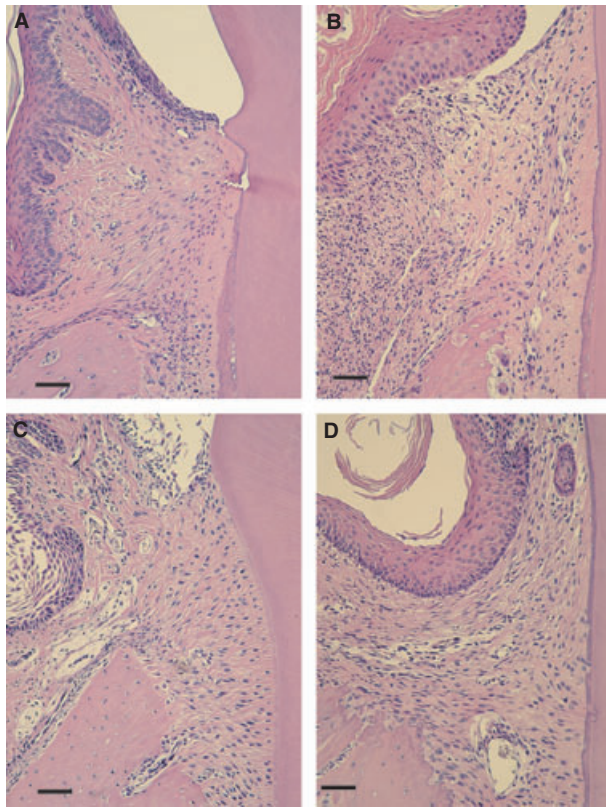
interferon- $\gamma$ . The daily doses of curcumin used by those authors were higher than the doses used in our study, but the authors did not observe a dose-dependent effect. This may be related to the different experimental models, or the maximal effective dose may have been reached.

Curcumin has also been shown to possess beneficial effects in alleviating arthritic symptoms in both humans and animal models (39). Indeed, there are clinical trials for the treatment of patients with rheumatoid arthritis and osteoarthritis with high doses of curcumin (40). Due to their nontoxic and

antimutagenic (41) nature, curcumin and other spice-derived principles hold promise in the treatment of arthritis. In animal models, carrageenan-induced paw inflammation was reduced in rats fed with curcumin at 30 mg/kg body weight (9). Histological changes, including infiltration of immune cells, synovial hyperplasia, cartilage destruction and bone erosion in the hindpaw histological sections, were extensively suppressed by oral administration of curcumin (4–100 mg/kg) in a dose-dependent manner (13). MMP-1 and MMP-3, critical factors in the degradation of joint cartilages, whose levels were prominently increased in the vehicle-treated group, were also reduced by curcumin. In regard to the modulation of intracellular signaling pathways, activation of JNK, but not ERK and p38 MAPK, was inhibited in a dose-dependent manner (13).

Although many studies (42–46) have investigated the effect of curcumin on modulation of different signaling pathways and transcription factors, such as AP-1 and MAP kinases, the best-characterized and most studied molecular target of curcumin is NF- $\kappa$ B. Inhibition of NF- $\kappa$ B may be one of the main mechanisms for the anti-inflammatory effects of curcumin. In the present study, we demonstrated that curcumin inhibited the activation of NF- $\kappa$ B in ligature-induced periodontal disease in rats. Nevertheless, it is possible that the inhibition of proinflammatory gene expression by curcumin is partly dependent on the modulation of signaling pathways other than NF- $\kappa$ B. Even though we have not observed modulation of p38 MAPK, another signaling pathway involved in the expression of proinflammatory cytokines and bone resorption (47–53), it is important to bear in mind that our data are derived from protein from the multiple cell types present in the periodontal microenvironment. Curcumin may have differential effects on signaling pathways according to the cell type, e.g. macrophages, lymphocytes, fibroblasts and osteoblasts.

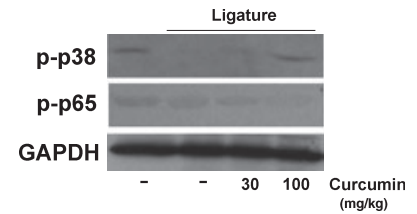
Besides its anti-inflammatory properties, curcumin is also being investigated for its therapeutic potential in cancer, as an angiogenesis inhibitor in



**Fig. 3.** Histological appearance of the gingival tissues according to the experimental group (control or ligature) and administration of curcumin (vehicle, 30 and 100 mg/kg curcumin). Tissues were harvested 15 d after ligatures were placed and administration of curcumin was started. Semi-serial sections 5  $\mu$ m thick were routinely processed and stained with hematoxylin and eosin. A total of three sections spaced by 100  $\mu$ m were evaluated for each first molar in a minimum of four animals in each experimental group. (A) An epithelial layer of regular thickness, dense connective tissue with a low cellular infiltrate and a smooth bone crest surface characterize the gingival tissues of control (nonligated) animals. (B) Placement of ligatures produced an increase of the thickness of the epithelial layer, an intense cellular infiltrate and irregular bone crest surface, with the presence of multinucleated osteoclast-like cells. In animals treated with 30 (C) and 100 mg/kg curcumin (D), the epithelial layer is a normal thickness and there is reduced cellular infiltrate. All images were obtained at  $\times 100$  magnification. Scale bar represent 100  $\mu$ m.

the treatment of corneal diseases (54) and in wound healing. Recent studies show that topical application of curcumin, incorporated in collagen vehicle, accelerated healing in experimental surgical wounds of 2 cm<sup>2</sup>, as indicated by enhanced cell proliferation and improved free radical scavenging in comparison with the wounds of negative control and collagen vehicle-treated rats (55). In agreement with these reports, we observed a more organized and higher collagen content in periodontally diseased tissues of animals treated with both doses of curcumin in comparison with the tissues of the vehicle-treated control group. Importantly,

we also evaluated intragastric administration of curcumin in the lipopolysaccharide model of experimental periodontal disease, which we have previously shown to present important differences in comparison with the ligature model used in this study (25), and observed very similar results (56), with a dose-independent inhibition of inflammatory cytokine gene expression, NF- $\kappa$ B activation and collagen degradation. This demonstrates the consistency of curcumin as an anti-inflammatory substance; however, the lack of inhibition of bone resorption was also consistent in the lipopolysaccharide model of experi-



**Fig. 4.** Modulation of nuclear factor- $\kappa$ B and p38 MAPK activation in gingival tissues by systemic administration of curcumin. The animals were killed after 15 d of curcumin (30 and 100 mg/kg) or vehicle administration and the tissues surrounding the lower first molars harvested. Total protein was isolated from gingival biopsies with a detergent-containing buffer (T-Per; Pierce) supplemented with protease and phosphatase inhibitor cocktails (Complete and Phos-Stop; Roche, Madison, WI, USA). Protein concentration was determined with a Lowry-based microassay (DC assay; Bio-Rad), and 60  $\mu$ g of each sample was diluted in lithium dodecyl sulfate-containing running buffer supplemented with dithiothreitol, heat-denatured, electrophoresed in 10% Tris-acrilamide gels and transferred to 0.2  $\mu$ m nitrocellulose membranes in a semi-dry transfer apparatus. The activation of the signaling pathways was assessed by the detection of phosphorylated forms of p65 (NF- $\kappa$ B) and p38 MAPK. Expression levels of constitutive housekeeping *GAPDH* are shown to confirm equal protein loading. The images are representative of samples from three animals in each experimental group.

mental periodontal disease (56). We speculate that this lack of effect on bone resorption may be related to a time delay to reach levels high enough for the biological effects of curcumin, since bone loss in the ligature model has recently been shown to occur by 3 d after placement of ligatures and stabilizes after the initial 11 d (57). These results are in contrast to *in vitro* studies demonstrating that curcumin inhibits RANKL-induced osteoclastogenesis (58,59) and in striking contrast to the inhibition of bone resorption assessed in the distal femur of rats with experimentally induced type 1 diabetes (60). We could not compare the dose of curcumin in that study, since the authors added curcumin directly to the rat chow and, even though there is no objective quantification of the dose of curcumin, it was estimated to be

120 mg/d (60), which is almost three times higher than our 100 mg/kg/d (or approximately 45 mg/d in a 450 g rat). The discrepancies may also be related to the peculiarities of each experimental model, but interestingly, these authors did not find regulation of RANKL mRNA expression by curcumin (60), similar to what we have observed at the protein level by immunohistochemistry in the diseased gingival tissues (data not shown). Thus, it is possible that the direct effects of curcumin on osteoclast precursor cells inhibiting osteoclastogenesis are offset *in vivo* by the lack of regulation of RANKL expression by stromal and immune cells. The modulatory effects of curcumin on alveolar bone turnover will be addressed in future studies.

Curcumin has a long history as a traditional herbal medicine and has established anti-inflammatory properties in animals following systemic administration (38,61,62). This compound is particularly interesting for therapeutic applications because its anti-inflammatory and antiproliferative effects are potent, occurring at micromolar concentrations. Moreover, clinical trials have shown no significant toxicity even when administered at 8 g/d (40). Although there are no reports of curcumin-induced toxicity associated with systemic administration, topical application may not only increase the potency of its effects but also prevent possible unwanted secondary effects in conditions associated with local chronic inflammation, such as periodontal diseases and rheumatoid arthritis. It is important to understand this as a proof-of-principle type of study in which the potential of curcumin to modulate inflammation associated with periodontal disease induced by ligatures *in vivo* was assessed for the first time. There are a number of important aspects to be considered that were not addressed in this initial study, such as the pharmacokinetics of curcumin, serum levels, alternative routes of administration (e.g. topical), vehicle used and its use with a therapeutic (i.e. after periodontal disease is established) or preventive emphasis (i.e. before induction of periodontal disease). In

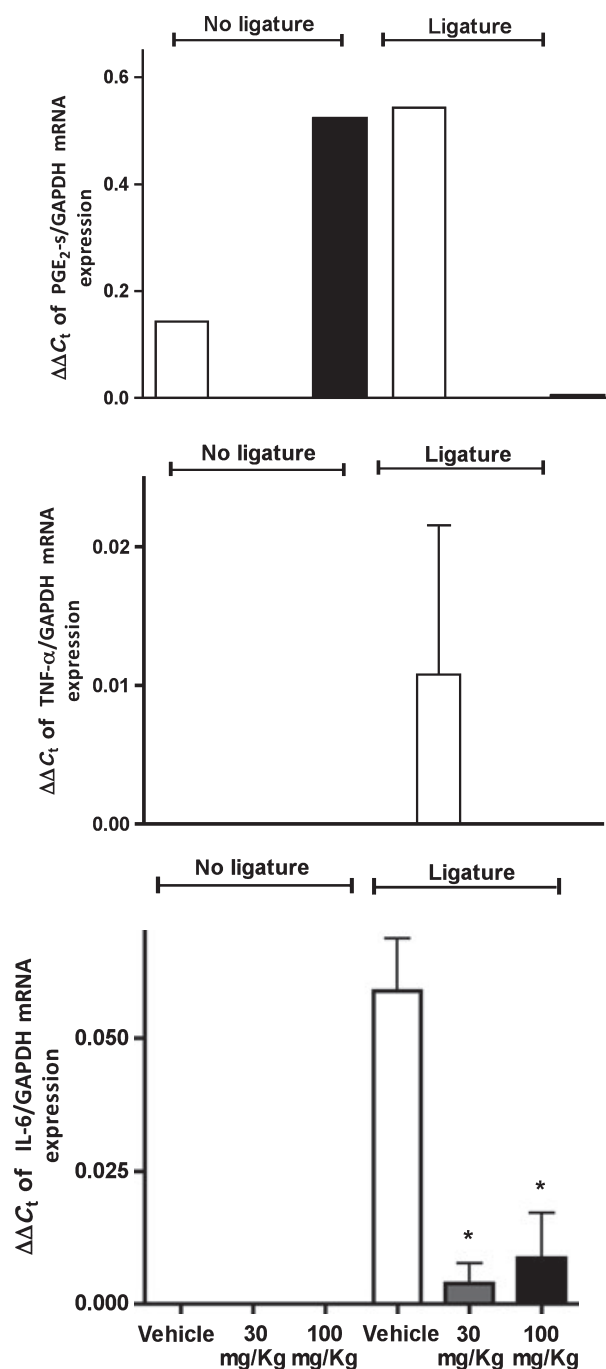


Fig. 5. Curcumin inhibits cytokine gene expression in experimental periodontitis. In the absence of periodontal disease, only *PGE<sub>2</sub> synthase (PGE<sub>2-s</sub>)* mRNA was significantly induced by the higher dose of curcumin in the absence of ligature-induced periodontal disease. The animals were treated with 30 or 100 mg/kg of curcumin by oral gavage daily for 15 d. Control animals received the same volume of the vehicle by oral gavage. Cotton ligatures were placed around the first molars of rats bilaterally to induce periodontal disease. After 15 d, the animals were killed and total RNA was isolated from gingival biopsies with ('Ligature') and without periodontal disease ('No ligature') and used for RT-qPCR performed with predesigned primers and probes for the indicated target genes and the house-keeping *GAPDH* using TaqMan reagents. The results were analysed by the  $\Delta C_t$  method and expression of target genes was normalized to *GAPDH* expression. \* Significant reduction ( $p < 0.05$ ) in comparison with vehicle control with ligatures. Bars indicate means and vertical lines standard error of the mean of at least three animals in each experimental group, except for *PGE<sub>2-s</sub>* mRNA analysis, for which the samples of three animals in each experimental group were pooled to enable detection and there are no error bars.

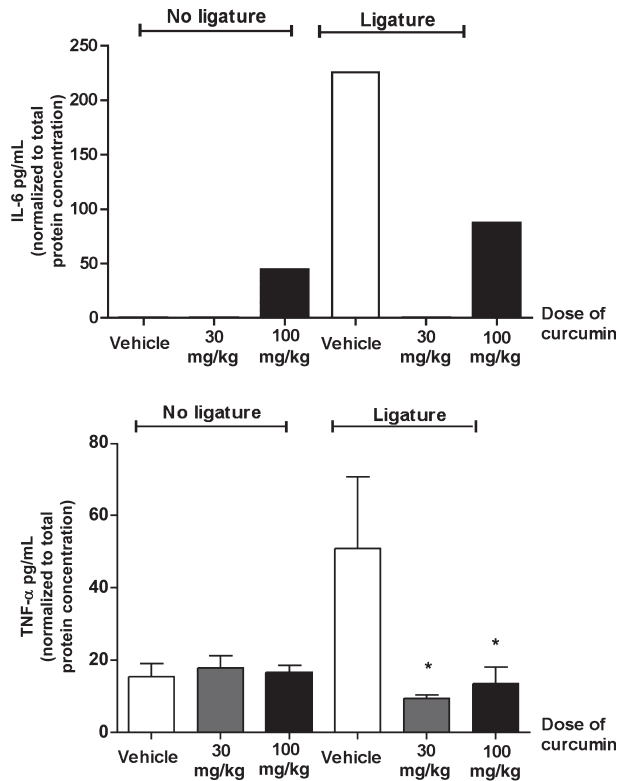


Fig. 6. Effective inhibition of both interleukin-6 (IL-6) and tumor necrosis factor- $\alpha$  (TNF- $\alpha$ ) production in periodontally diseased tissues by curcumin. In the absence of ligatures, the higher dose of curcumin was associated with increased production of IL-6, whereas TNF- $\alpha$  production was not affected. Gingival tissues around both lower first molars with ('Ligature') and without experimentally induced periodontal disease ('No ligature') were collected after 15 d of administration of curcumin (30 or 100 mg/kg) by oral gavage. Control animals received the same volume of vehicle. Total protein was extracted and used in ELISAs to quantify the expression of the target cytokines. These tests were performed according to the manufacturer's instructions, and the results for each sample were normalized to the concentration of total proteins determined by a Lowry-based microassay (DC assay; Bio-Rad). \* Significant difference ( $p < 0.05$ ) in comparison with vehicle control in animals with ligature-induced periodontitis. Bars indicate means and vertical lines standard error of the mean of at least three animals in each experimental group. The IL-6 concentration was determined in pooled samples from three animals in each experimental group due to the low level of expression, and the bars indicate the average of the triplicate measurement from these pooled samples.

summary, our results confirm and extend our prior *in vitro* observations (not shown), as well as our *in vivo* observations in a different experimental model of periodontal disease (56) and suggest that curcumin is a candidate as an anti-inflammatory therapeutic strategy for periodontal diseases.

### Acknowledgements

Financial support was provided by the Brazilian Federal Government through the National Council for Scientific and Technological Development (CNPq)

and Coordination for Improvement of Higher Education Personnel (CAPES, no. 4638-05), and by the National Institutes of Health – National Institute of Dental and Craniofacial Research (1R01DE018290) and National Center for Research Resources (P20RR017696). The authors are also very grateful to the laboratory technicians Jose Antonio Sampaio Zuanon (Department of Physiology and Pathology, Faculdade de Odontologia de Araraquara, Univ Estadual Paulista, UNESP) and Ana Claudia Gregolin Costa Miranda (Department

of Diagnosis and Surgery, Faculdade de Odontologia de Araraquara, Univ Estadual Paulista, UNESP) for their collaboration with the histological processing and to Steven A. Goldstein, PhD (Director, Orthopaedic Research Laboratories, University of Michigan, Ann Arbor, MI, USA) and Jaclynn Mary Kreider (Associate Research Laboratory Technician, Orthopaedic Research Laboratories, University of Michigan, Ann Arbor, MI, USA) for their collaboration with the micro-computed tomography analysis.

### References

- Sharma RA, Gescher AJ, Steward WP. Curcumin: the story so far. *Eur J Cancer* 2005;**41**:1955–1968.
- Sharma RA, Euden SA, Platton SL *et al*. Phase I clinical trial of oral curcumin: biomarkers of systemic activity and compliance. *Clin Cancer Res* 2004;**10**:6847–6854.
- Punithavathi D, Venkatesan N, Babu M. Curcumin inhibition of bleomycin-induced pulmonary fibrosis in rats. *Br J Pharmacol* 2000;**131**:169–172.
- Kim HY, Park EJ, Joe EH, Jou I. Curcumin suppresses Janus kinase-STAT inflammatory signaling through activation of Src homology 2 domain-containing tyrosine phosphatase 2 in brain microglia. *J Immunol* 2003;**171**:6072–6079.
- Duvoix A, Blasius R, Delhalle S *et al*. Chemopreventive and therapeutic effects of curcumin. *Cancer Lett* 2005;**223**:181–190.
- Rao CV, Rivenson A, Simi B, Reddy BS. Chemoprevention of colon carcinogenesis by dietary curcumin, a naturally occurring plant phenolic compound. *Cancer Res* 1995;**55**:259–266.
- Anonymous. Clinical development plan: curcumin. *J Cell Biochem Suppl* 1996;**26**: 72–85.
- Swarnakar S, Ganguly K, Kundu P, Banerjee A, Maity P, Sharma AV. Curcumin regulates expression and activity of matrix metalloproteinases 9 and 2 during prevention and healing of indomethacin-induced gastric ulcer. *J Biol Chem* 2005;**280**:9409–9415.
- Joe B, Rao UJ, Lokesh BR. Presence of an acidic glycoprotein in the serum of arthritic rats: modulation by capsaicin and curcumin. *Mol Cell Biochem* 1997;**169**:125–134.
- Kim GY, Kim KH, Lee SH *et al*. Curcumin inhibits immunostimulatory function of dendritic cells: MAPKs and translocation of NF- $\kappa$ B as potential targets. *J Immunol* 2005;**174**:8116–8124.

11. Gulcubuk A, Altunatmaz K, Sonmez K *et al.* Effects of curcumin on tumour necrosis factor- $\alpha$  and interleukin-6 in the late phase of experimental acute pancreatitis. *J Vet Med* 2006;**53**:49–54.
12. Moon DO, Kim MO, Choi YH, Park YM, Kim GY. Curcumin attenuates inflammatory response in IL-1 $\beta$ -induced human synovial fibroblasts and collagen-induced arthritis in mouse model. *Int Immunopharmacol* 2010;**10**:605–610.
13. Mun SH, Kim HS, Kim JW *et al.* Oral administration of curcumin suppresses production of matrix metalloproteinase (MMP)-1 and MMP-3 to ameliorate collagen-induced arthritis: inhibition of the PKC $\delta$ /JNK/c-Jun pathway. *J Pharmacol Sci* 2009;**111**:13–21.
14. Jurenka JS. Anti-inflammatory properties of curcumin, a major constituent of *Curcuma longa*: a review of preclinical and clinical research. *Altern Med Rev* 2009;**14**:141–153.
15. Mathy-Hartert M, Jacquemond-Collet I, Priem F, Sanchez C, Lambert C, Henrotin Y. Curcumin inhibits pro-inflammatory mediators and metalloproteinase-3 production by chondrocytes. *Inflamm Res* 2009;**58**:899–908.
16. Epstein J, Docena G, MacDonald TT, Sanderson IR. Curcumin suppresses p38 mitogen-activated protein kinase activation, reduces IL-1 $\beta$  and matrix metalloproteinase-3 and enhances IL-10 in the mucosa of children and adults with inflammatory bowel disease. *Br J Nutr* 2010;**103**:824–832.
17. Hanai H, Sugimoto K. Curcumin has bright prospects for the treatment of inflammatory bowel disease. *Curr Pharm Des* 2009;**15**:2087–2094.
18. Holt PR, Katz S, Kirshoff R. Curcumin therapy in inflammatory bowel disease: a pilot study. *Dig Dis Sci* 2005;**50**:2191–2193.
19. Kirkwood KL, Cirelli JA, Rogers JE, Giannobile WV. Novel host response therapeutic approaches to treat periodontal diseases. *Periodontol 2000* 2007;**43**:294–315.
20. Graves DT, Oskoui M, Volejnikova S *et al.* Tumor necrosis factor modulates fibroblast apoptosis, PMN recruitment, and osteoclast formation in response to *P. gingivalis* infection. *J Dent Res* 2001;**80**:1875–1879.
21. Graves DT, Jiang Y, Valente AJ. The expression of monocyte chemoattractant protein-1 and other chemokines by osteoblasts. *Front Biosci* 1999;**4**:D571–D580.
22. Jagetia GC, Rajanikant GK. Curcumin treatment enhances the repair and regeneration of wounds in mice exposed to hemibody gamma-irradiation. *Plast Reconstr Surg* 2005;**115**:515–528.
23. Maheshwari RK, Singh AK, Gaddipati J, Srimal RC. Multiple biological activities of curcumin: a short review. *Life Sci* 2006;**78**:2081–2087.
24. Sidhu GS, Singh AK, Thaloor D *et al.* Enhancement of wound healing by curcumin in animals. *Wound Repair Regen* 1998;**6**:167–177.
25. Garcia de Aquino S, Manzolli Leite FR, Stach-Machado DR, Francisco da Silva JA, Spolidorio LC, Rossa C Jr. Signaling pathways associated with the expression of inflammatory mediators activated during the course of two models of experimental periodontitis. *Life Sci* 2009;**84**:745–754.
26. Fu Y, Zheng S, Lin J, Ryerse J, Chen A. Curcumin protects the rat liver from CCl<sub>4</sub>-caused injury and fibrogenesis by attenuating oxidative stress and suppressing inflammation. *Mol Pharmacol* 2008;**73**:399–409.
27. Lee HJ, Kang IK, Chung CP, Choi SM. The subgingival microflora and gingival crevicular fluid cytokines in refractory periodontitis. *J Clin Periodontol* 1995;**22**:885–890.
28. Offenbacher S, Heasman PA, Collins JG. Modulation of host PGE<sub>2</sub> secretion as a determinant of periodontal disease expression. *J Periodontol* 1993;**64**:432–444.
29. Ejeil AL, Gaultier F, Igondjo-Tchen S *et al.* Are cytokines linked to collagen breakdown during periodontal disease progression? *J Periodontol* 2003;**74**:196–201.
30. Gamonal J, Acevedo A, Bascones A, Jorge O, Silva A. Levels of interleukin-1 $\beta$ , -8, and -10 and RANTES in gingival crevicular fluid and cell populations in adult periodontitis patients and the effect of periodontal treatment. *J Periodontol* 2000;**71**:1535–1545.
31. Geivelis M, Turner DW, Pederson ED, Lamberts BL. Measurements of interleukin-6 in gingival crevicular fluid from adults with destructive periodontal disease. *J Periodontol* 1993;**64**:980–983.
32. Gorska R, Gregorek H, Kowalski J, Laskus-Perendyk A, Syczewska M, Madalinski K. Relationship between clinical parameters and cytokine profiles in inflamed gingival tissue and serum samples from patients with chronic periodontitis. *J Clin Periodontol* 2003;**30**:1046–1052.
33. Stashenko P, Jandinski JJ, Fujiyoshi P, Rynar J, Socransky SS. Tissue levels of bone resorptive cytokines in periodontal disease. *J Periodontol* 1991;**62**:504–509.
34. Gukovsky I, Reyes CN, Vaquero EC, Gukovskaya AS, Pandol SJ. Curcumin ameliorates ethanol and nonethanol experimental pancreatitis. *Am J Physiol* 2003;**284**:G85–G95.
35. Plummer SM, Holloway KA, Manson MM *et al.* Inhibition of cyclo-oxygenase 2 expression in colon cells by the chemopreventive agent curcumin involves inhibition of NF- $\kappa$ B activation via the NIK/IKK signalling complex. *Oncogene* 1999;**18**:6013–6020.
36. Gaddipati JP, Sundar SV, Calemine J, Seth P, Sidhu GS, Maheshwari RK. Differential regulation of cytokines and transcription factors in liver by curcumin following hemorrhage/resuscitation. *Shock* 2003;**19**:150–156.
37. Goel A, Kunnumakkara AB, Aggarwal BB. Curcumin as “Curecumin”: from kitchen to clinic. *Biochem Pharmacol* 2008;**75**:787–809.
38. Banerjee M, Tripathi LM, Srivastava VM, Puri A, Shukla R. Modulation of inflammatory mediators by ibuprofen and curcumin treatment during chronic inflammation in rat. *Immunopharmacol Immunotoxicol* 2003;**25**:213–224.
39. Ammon HP, Wahl MA. Pharmacology of *Curcuma longa*. *Planta Med* 1991;**57**:1–7.
40. Hsu CH, Cheng AL. Clinical studies with curcumin. *Adv Exp Med Biol* 2007;**595**:471–480.
41. Polasa K, Sesikaran B, Krishna TP, Krishnaswamy K. Turmeric (*Curcuma longa*)-induced reduction in urinary mutagens. *Food Chem Toxicol* 1991;**29**:699–706.
42. Chen D, Nie M, Fan MW, Bian Z. Anti-inflammatory activity of curcumin in macrophages stimulated by lipopolysaccharides from *Porphyromonas gingivalis*. *Pharmacology* 2008;**82**:264–269.
43. Balasubramanian S, Eckert RL. Curcumin suppresses AP1 transcription factor-dependent differentiation and activates apoptosis in human epidermal keratinocytes. *J Biol Chem* 2007;**282**:6707–6715.
44. Suh HW, Kang S, Kwon KS. Curcumin attenuates glutamate-induced HT22 cell death by suppressing MAP kinase signaling. *Mol Cell Biochem* 2007;**298**:187–194.
45. Kim SJ, Hellerstein MK. Pharmacological doses of dietary curcumin increase colon epithelial cell proliferation in vivo in rats. *Phytother Res* 2007;**21**:995–998.
46. Cho JW, Park K, Kweon GR *et al.* Curcumin inhibits the expression of COX-2 in UVB-irradiated human keratinocytes (HaCaT) by inhibiting activation of AP-1: p38 MAP kinase and JNK as potential upstream targets. *Exp Mol Med* 2005;**37**:186–192.
47. Rossa C Jr, Liu M, Bronson P, Kirkwood KL. Transcriptional activation of MMP-13 by periodontal pathogenic LPS requires p38 MAP kinase. *J Endotoxin Res* 2007;**13**:85–93.
48. Sartori R, Li F, Kirkwood KL. MAP kinase phosphatase-1 protects against inflammatory bone loss. *J Dent Res* 2009;**88**:1125–1130.
49. Rossa C Jr., Liu M, Patil C, Kirkwood KL. MKK3/6-p38 MAPK negatively regulates murine MMP-13 gene expression induced by IL-1 $\beta$  and TNF- $\alpha$  in

- immortalized periodontal ligament fibroblasts. *Matrix Biol* 2005;**24**:478–488.
50. Rossa C, Ehmann K, Liu M, Patil C, Kirkwood KL. MKK3/6-p38 MAPK signaling is required for IL-1beta and TNF-alpha-induced RANKL expression in bone marrow stromal cells. *J Interferon Cytokine Res* 2006;**26**:719–729.
  51. Patil C, Zhu X, Rossa C Jr., Kim YJ, Kirkwood KL. p38 MAPK regulates IL-1beta induced IL-6 expression through mRNA stability in osteoblasts. *Immunol Invest* 2004;**33**:213–233.
  52. Patil C, Rossa C Jr, Kirkwood KL. *Actinobacillus actinomycetemcomitans* lipopolysaccharide induces interleukin-6 expression through multiple mitogen-activated protein kinase pathways in periodontal ligament fibroblasts. *Oral Microbiol Immunol* 2006; **21**:392–398.
  53. Mbalaviele G, Anderson G, Jones A *et al*. Inhibition of p38 mitogen-activated protein kinase prevents inflammatory bone destruction. *J Pharmacol Exp Ther* 2006; **317**:1044–1053.
  54. Chen M, Hu DN, Pan Z, Lu CW, Xue CY, Aass I. Curcumin protects against hyperosmoticity-induced IL-1beta elevation in human corneal epithelial cell via MAPK pathways. *Exp Eye Res* 2010; **90**:437–443.
  55. Gopinath D, Ahmed MR, Gomathi K, Chitra K, Sehgal PK, Jayakumar R. Dermal wound healing processes with curcumin incorporated collagen films. *Biomaterials* 2004;**25**:1911–1917.
  56. Guimaraes MR, Coimbra LS, de Aquino SG, Spolidorio LC, Kirkwood K L, Rossa C Jr. Curcumin modulates the immune response associated with LPS-induced periodontal disease in rats. *Innate Immun* 2011 (in press).
  57. Liu L, Li C, Cai X, Xiang J, Cao Z, Dong W. The temporal expression and localization of extracellular matrix metalloproteinase inducer (EMMPRIN) during the development of periodontitis in an animal model. *J Periodontal Res* 2010;**45**:541–549.
  58. Bharti AC, Takada Y, Aggarwal BB. Curcumin (diferuloylmethane) inhibits receptor activator of NF-kappa B ligand-induced NF-kappa B activation in osteoclast precursors and suppresses osteoclastogenesis. *J Immunol* 2004;**172**:5940–5947.
  59. Oh S, Kyung TW, Choi HS. Curcumin inhibits osteoclastogenesis by decreasing receptor activator of nuclear factor-kappaB ligand (RANKL) in bone marrow stromal cells. *Mol Cells* 2008;**26**:486–489.
  60. Hie M, Yamazaki M, Tsukamoto I. Curcumin suppresses increased bone resorption by inhibiting osteoclastogenesis in rats with streptozotocin-induced diabetes. *Eur J Pharmacol* 2009;**621**:1–9.
  61. Brouet I, Ohshima H. Curcumin, an anti-tumour promoter and anti-inflammatory agent, inhibits induction of nitric oxide synthase in activated macrophages. *Biochem Biophys Res Commun* 1995;**206**:533–540.
  62. Miquel J, Bernd A, Sempere JM, Diaz-Alperi J, Ramirez A. The curcuma antioxidants: pharmacological effects and prospects for future clinical use. A review. *Arch Gerontol Geriatr* 2002;**34**:37–46.